

Original Research Article

EVALUATION OF ANATOMICAL VARIATIONS IN PARANASAL SINUSES ON COMPUTED TOMOGRAPHY SCAN OF CASES WITH SINONASAL PATHOLOGY

Saumya Tiwari¹, Avneesh Kumar², Sandeep Kaushik³

¹ENT consultant District Hospital (male) Ayodhya, Uttar Pradesh, India.

²Assistant Professor ENT Government medical college, Kannauj, Uttar Pradesh, India.

³Professor ENT Government medical college, Kannauj, Uttar Pradesh, India.

Received : 30/09/2024
Received in revised form : 28/11/2024
Accepted : 13/12/2024

Corresponding Author:

Dr. Avneesh Kumar,
Assistant Professor ENT Government
medical college, Kannauj, Uttar
Pradesh, India.
Email: dravi1314@gmail.com

DOI: 10.70034/ijmedph.2024.4.190

Source of Support: Nil,
Conflict of Interest: None declared

Int J Med Pub Health
2024; 14 (4); 1032-1036

ABSTRACT

Background: The anatomy of paranasal sinuses is very complicated. Evaluation of the location and extent of sinonasal diseases by radiologic evaluation of the paranasal sinuses is essential in planning surgical intervention. Plain radiography, computed tomography and magnetic resonance imaging are applied in evaluating the sinuses. Computed tomography is considered the radiologic method of choice in completely delineating the normal anatomy and anatomical variants of the paranasal sinuses and it is extremely useful in the pre-operative planning of endonasal surgeries. Keeping in view the potency of CT scans the present study has been undertaken to assess the anatomic variations of the paranasal sinuses by means of CT scans in patients.

Material and Methods: The prospective non-randomized study was conducted in the department of Ear, Nose & Throat, GSVM Medical College and LLR & Associated Hospitals, Kanpur from January 2018 to October 2019. Total 50 patients between 15-50 years of age and with chronic rhinosinusitis not responding to three weeks of medical treatment were included in the study. The routine investigations like CBC, ESR, RBS, LFTs, KFTs, Serum electrolyte and X-ray PNS water views were conducted on the patients of study group during this period along with the CT PNS.

Results: 50 Patients between 15-50 years of age were included in the study. Out of 50 patients, 32 (64%) were males, while 18 (36%) were females. Most of the patients i.e. 40% were found to belong in the age group of 15-20 years. Out of 50 patients 5(10%) patients presented with complications as a result of nasal surgery. As per the study out of 50 patients 45(90%) have shown improvement after nasal surgery.

Conclusion: Computed Tomography of the paranasal sinuses has improved the visualization of paranasal sinus anatomy and has allowed greater accuracy in evaluating paranasal sinus disease. It evaluates the osteomeatal complex anatomy which is not possible with plain radiographs.

Key Words: Chronic Rhinosinusitis (CRS), Paranasal sinus(PNS), Computed Tomography (CT).

INTRODUCTION

Chronic rhinosinusitis (CRS) is a common disease affecting over 30 million individuals globally each year with more than 200,000 people annually requiring surgical intervention. For the management of diseases affecting sinuses, their basic knowledge about anatomy is must. Sinus surgery is a common

procedure which requires a radiological description of the anatomy and its anatomical variations in nose and PNS. Though the importance of anatomical variations of osteomeatal complex in the etiology of nose and paranasal disease is still in debate but knowledge of these variations in each patient is important before planning for surgery to avoid

injury to surrounding important structures like the orbit and the brain.

Computed tomographic (CT) scanning of the face has become a standard part of oromaxillofacial imaging. Variations in paranasal sinus anatomy as shown on CT scans is of potential significance, for it may pose risks during surgery or predispose to certain pathologic conditions and diseases. Studying the relative frequency and concurrence of these variations in a given population and comparing the results with that of other races may yield important hints in medical decision making and surgical planning for all patients. Variations in intranasal and sinus anatomy amongst other factors have been implicated in the etiology of chronic and recurrent rhinosinusitis and CT imaging has become an important diagnostic tool as it provides detailed information and an unparalleled view of the sinuses especially the bony anatomy. CT scan delineates areas which are poorly shown on plain X-ray films like anterior and posterior ethmoid cells, sphenoid sinus and osteomeatal complex. CT scan is effective in demonstrating predisposing causes of rhinosinusitis like anatomical variation, trauma and tumour which can cause narrowing of the osteomeatal complex and sinus drainage channels. It is extremely useful in providing the road map prior to endoscopic sinus surgery.

The criteria of Rhinosinusitis Task Force of AAO-HNS to define and diagnose chronic sinusitis is, presence of two or more major factors or one major and two minor factors and duration for >12 consecutive weeks or >12 weeks of physical findings. Importantly, the sinus and allergy health partnership (SAHP) 2003 also incorporates CT imaging of the sinuses and endoscopy for confirming the diagnosis. The clinical diagnosis of chronic sinusitis is somewhat difficult, due to difficulty in defining the disease and a variety of presenting signs and symptoms. Keeping in view the potency of CT scans the present study has been undertaken to assess the anatomic variations of the paranasal sinus by means of CT scans in patients referred to Department of Ear, Nose, and Throat Surgery with the following objectives:

1. To study incidence of anatomical variation on radiology in patients with sinonasal pathology.
2. To study the effect of anatomical variation on treatment outcome of the cases under study.

MATERIALS AND METHODS

The prospective non-randomized study was conducted in the department of Ear, Nose & Throat, GSVM Medical College and LLR & Associated Hospitals, Kanpur from January 2018 to October 2019 on patients who were admitted from casualty and outpatients department with a diagnosis of anatomical variations on radiology in patients with sino-nasal pathology. Patients between 15-50 year of age and with chronic rhinosinusitis not

responding to three weeks of medical treatment were included in the study.

Method for collection of data

An informed consent was taken from all patients included in the study. A detailed history was taken and complete clinical examination was done. Raw data was collected, tabulated and was analysed statistically using the most appropriate statistical tools. Minimum of 50 patients with sino-nasal pathology were taken under the study. The study was conducted for a period of 1½ years from January 2018 to October 2019. The routine investigations like CBC, ESR, RBS, LFTs, KFTs, Serum electrolyte and X-ray PNS water views were conducted on the patients of study group during this period along with the CT PNS. Ethical committee approval was also obtained by the institute's Ethical committee.

RESULTS

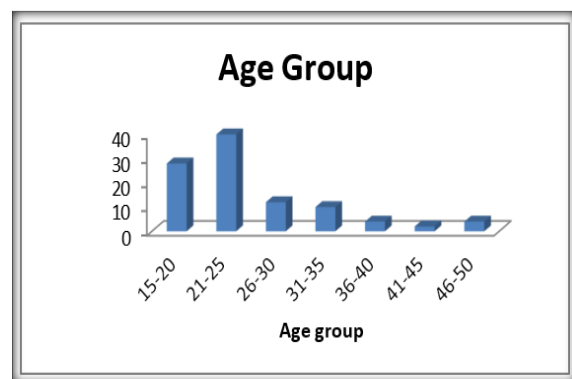


Figure 1 Age Distribution of Patients

In the present study, 14 patients (28%) were in the age group of 15 – 20 years. 20 (40%) patients were in the age group 21 – 25 years, 6 patients (12%) were in the age group of 26 – 30 years, 5 patients (10%) were in the age group of 31 – 35 years, 02 patients (04%) were in the age group of 36 – 40 years, 1 patient (02%) was in the age group of 41 – 45 years and 02 patients (04%) were in the age group of 46 – 50 years. Out of 50 patients, 32 (64%) were males, while 18 (36%) were females.

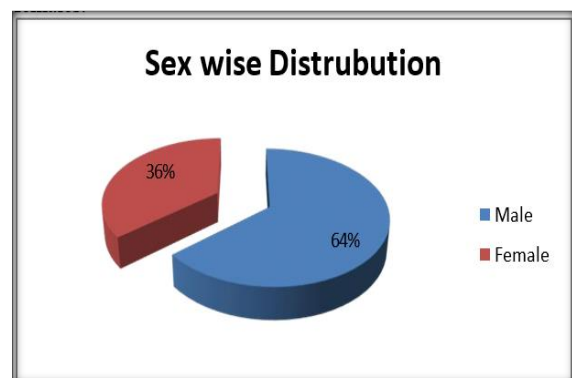


Figure 2: Sex wise distribution of Patients

Table 1: Distribution of Anatomical Variations

VARIATIONS	NO OF PATIENTS	PERCENTAGE
DNS	32	64
Concha Bullosa	17	34
Variations of Uncinate Attachment	8	16
Paradoxical MT	5	10
ANC	5	10
HC	3	6
OC	2	4
Pneumatised Septum	7	14
Enlarged BE	4	8
Accessory Maxillary Ostia	1	2

Table 2: Post Surgery outcome with anatomical variations

COMPLICATIONS	NO OF PATIENTS	PERCENTAGE
Hemorrhage	3	6
Septal Perforation	0	0
Saddle Nose	0	0
Infection	1	2
Persistence of Septal Deformity	1	2
Nasal Tip Depression	0	0

Out of 50 patients 5(10%) patients presented with complications as a result of nasal surgery.

Table 3: Post Surgery Outcome with Anatomical Variations

Improvement of Symptoms	NO. OF PATIENTS	PERCENTAGE
Nasal Obstruction	23	46
Nasal Discharge	10	20
Hyposmia	2	4
Headache	5	10
Epistaxis	3	6
Respiratory Difficulty	1	2
Post Nasal Drip	1	2

As per the study out of 50 patients 45(90%) have shown improvement after nasal surgery.

DISCUSSION

The Surgical Management of CRS has evolved over the years. External facial incisions, extensive nasal packing and prolonged hospital stays have been replaced by minimally invasive surgery. This involves opening the obstructed ostia to provide normal ventilation with preservation of adjacent mucosa. While excellent results have been reported in the literature to date, given the close relation of the paranasal sinuses to important structures such as the orbit and skull base, if complications occur in surgery, they are usually dangerous and harmful. Anatomical variations in the sinonasal region are common. Recent advances in CT Scanning and the widespread of ESS, as well as the presence of universal agreement in the variation nomenclature and terminology has made the extent of these variations apparent. Local anatomic variations including concha bullosa, deviated nasal septum (DNS), Haller cells, paradoxical middle turbinates, agger nasi cells and many others may be the source of middle meatal obstruction and subsequent rhinosinusitis.

Nasal Septum Deviaton

Nasal septum is fundamental in the development of the nose and paranasal sinuses. It is the epiphyseal platform for the development of the facial skeleton. 64% of the patients in our study presented with nasal septal deviation. Deviated nasal septum causes a decrease in the critical area of the osteomeatal unit

predisposing to obstruction and related complications. Similar findings were observed by Perez et al,^[1] who reported the prevalence of deviated nasal septum to be about 80%. In fact in various studies the finding of nasal septal deviation ranged from 14.1% to 80%. Dutra and Marchiore et al,^[2] 14.1% ,Arslan et al.344%, Dua et al,^[4] and Asruddin et al,^[5] found prevalence of 44% and 38% of deviate nasal septum in their respective studies. Stallmann et al,^[6] and Mamtha et al,^[7] also reported prevalence of 60 % and 65% deviated nasal septum in chronic rhino sinusitis cases respectively.

Concha Bullosa

Concha bullosa (pneumatised middle turbinate) has been implicated as a possible aetiological factor in the causation of recurrent chronic sinusitis. It is due to its negative influence on paranasal sinus ventilation and mucociliary clearance in the middle meatus region as quoted by Tonai et al,^[8] Concha bullosa was seen in 34% of the chronic rhinosinusitis cases which is almost similar to as reported by Bolger et al,^[9] and Yousem et al,^[10] respectively. Perez-Pinas et al,^[11] reported higher prevalence of concha bullosa i.e.73% and 67% in chronic rhino sinusitis cases. The prevalence of concha bullosa in our study is on the higher side when compared to the findings of Stallmann et al,^[6] Maru et al,^[11] Wani et al,^[12] Dua et al,^[4] Asruddin et al,^[5] Mamatha et al.7, Zinreich et al,^[13] Llyod et al,^[14] and Weinberger et al,^[15] reported further less

prevalence of about 36%, 30%, 28%, 16%, 15% 14% and 15% respectively.

Paradoxically Curved Middle Turbinate

The Middle turbinate may be paradoxically curved i.e., bent in the reverse direction. This may lead to impingement of the middle meatus and thus to sinusitis. It was found in 10% of the patients; the prevalence is similar to that of 12% by Asruddin et al,^[5] and 15% by Llyod et al,^[14] Aggar Nasi Cell

Aggar nasi cell lie just anterior to the anterosuperior attachment of the middle turbinate and frontal recess. This can invade the lacrimal bone or the ascending process of maxilla. This cell was observed in 10% of patients in our study. Similar results were observed by Liu X et al,^[16] and Llyod et al,^[14] who reported the prevalence of aggar nasi cell as 7.8% and 8.5% in chronic rhinosinusitis cases whereas in the study by Dua et al,^[4] agger nasi cells were found to be present in 8% patients. The prevalence is very less as compared to 98.5% by Bolger,^[9] 88.5% by Maru,^[11] 86.7% by Tonai and Baba,^[8] and 48% by Asruddin et al.^[5]

Haller's Cell

Zinreich et al,^[13] and Kennedy et al,^[17] described Haller's cells as ethmoid air cells found inferior to the ethmoid bulla adhering to the roof of the maxillary sinus, in continuity with the proximal infundibulum, which formed part of the lateral wall of the infundibulum. They are considered as ethmoid cells that grow into the floor of orbit and may narrow the adjacent ostium of the maxillary sinus especially if they become infected. The Haller cell is thought to cause chronic sinusitis cases by impinging on the ostium of the maxillary sinus and infundibulum by inhibiting the ciliary function, leading to obstruction of the ostium. The prevalence of Haller's cells in our study was 6%. Similar findings were observed by Liu X et al,^[16] who reported the prevalence of about 1 % of Haller cells in 297 chronic rhino sinusitis cases in a study conducted in SunYat Sen University of Medical Sciences. This is again very less as compared to that reported by Kayalioglu et al,^[18] 5.5%, Dua et al,^[4] 16%, Llyod et al,^[14] 15%, Perez-Pinas et al. 20%, Tonai and Baba 836%, Bolger et al,^[9] 45.9%, Maru et al,^[11] 36%, Alkire BC et al,^[19] 39.9% and Asruddin et al,^[5] 28% respectively.

Onodi Cell

Onodi cell is the most posterior ethmoid air cell that extends laterally. This extension is near the carotid canal and close to the optic nerve, which emphasizes the clinical importance of considering this anatomic variation prior to any attempt for invasive intervention. The surgeon must pay close attention to the occasional Onodi cell in pre-operative evaluation to avoid potential complications of ESS. Onodi cell was found in 4% patients in the current study. Other studies have reported Onodi cell presence from 0% to 9%.

Variation in uncinata attachment

The uncinata process is a key bony structure of the lateral wall of the nasal cavity. Together with the ethmoid bulla, it limits the semilunar hiatus and the ethmoid infundibulum, where the frontal and maxillary sinuses drain. The upper edge of the uncinata process may present lateral, medial or anterior deviation with respect to the middle nasal meatus, appearing as a second middle concha. When the deviation is lateral, it can result in narrowing of the semilunar hiatus and infundibulum, jeopardising their patency. When the deviation is medial, the uncinata process makes contact with the middle nasal meatus, threatening its permeability. The exact incidence of these variants is not known. Earwaker (1993),^[20] observed a horizontal orientation of the uncinata process, unilaterally or bilaterally, in 19% of cases (ours were 16%). In 95% of these, the variant was associated with a great ethmoidal bulla and in some cases with contralateral septal deviation

CONCLUSION

Computed Tomography of the paranasal sinuses has improved the visualization of paranasal sinus anatomy and has allowed greater accuracy in evaluating paranasal sinus diseases. It evaluates the osteomeatal complex anatomy which is not possible with plain radiographs. Anatomical variations studied on CT scan are found to block the OMC and cause chronic sinusitis. The blockade in the OMC leads to impaired drainage of maxillary, frontal and anterior ethmoid thus causing chronic sinusitis. Thus, this study has reemphasized the concept that osteomeatal complex is the key factor in the causation of chronic sinusitis. Removal of disease in Osteomeatal complex region is the basic principle of FESS which is best appreciated on CT scan.

Declarations

Funding: No funding source.

Conflict of interest: None declared

Ethical approval: The study was approved by Institutional Ethics Committee

REFERENCES

1. Perez-Pinas, Sabate J, Carmona A, Catalina-Herrera CJ, Jimenez Castellanos J. Anatomical variations in the human paranasal sinus region studied by CT. *J Anat*. 2000; 197:221-27. Scribano E, Ascenti G, Casio F, Racchiusa S, Salamone I. Computerized tomography in the evaluation of anatomic variations of the osteomeatal complex. *Radio Med (Torino)*. 1993; 86:195-99
2. Dutra DL, Marchiori E. Helical CT of the paranasal sinuses in children: evaluation of inflammatory sinus disease. *Radiol Bras*. 2002; 35:161-69.
3. Arslan G. Concha bullosa and nasal septum deviation. *Am J Neuroradiol*. 2005; 26:1882.
4. Dua K, Chopra H, Khurans As and Munjal M. CT scan variations in chronic sinusitis. *Ind J Radio Imag*. 2005; 15:315-20.
5. Asruddin, Yadav SPS, Yadav RK, Singh J. Low dose CT in chronic sinusitis. *Indian J Otolaryngol*. 1999-2000; 52:17-22.

6. Stallman JS, Lobo JN, Som PM. The incidence of concha bullosa and its relationship to nasal septal deviation and paranasal sinus disease. *AM J Neuroradiol.* 2004; 25:1613-18.
7. Mamtha H, Shamasundar NM, Bharathi MB, Prasanna LC. Variations of osteomeatal complex and its applied anatomy: a CT scan study. *Indian J Sci Technol.*2010; 3:904-07.
8. Tonai A, Baba S. Anatomic variations of the bone in sinonasal CT. *Acta Otolaryngol Suppl.*1996;525:9-13.
9. Bolger WE, Butzin CA, Parsons DS. Paranasal sinus bony anatomic variation and mucosal abnormalities: CT analysis for endoscopic sinus surgery. *Laryngoscope* 1991; 101:56-64.
10. Yousem DM. Imaging of sinonasal inflammatory disease. *Radiology* 1993; 188:303-14.
11. Maru YK, Gupta Y. Concha bullosa: frequency and appearances on sinonasal CT. *Indian J Otolaryngol.* 1999-2000; 52:40-45.
12. Wani AA, Kanotra S, Lateef M, Ahmad R, Qazi SM, Ahmad S. CT scan evaluation of the osteomeatal complex. *Indian J Otolaryngol Head Neck Surg.* 2009;61:163-68.
13. Zinreich SJ, Kennedy DW, Gayler BW. Computer tomography of nasal cavity and paranasal sinuses: An evaluation of anatomy for endoscopic sinus surgery. *Clear images.* 1988;1:2-10.
14. Llyod GA, Lund VJ, Scadding GK. CT of the paranasal sinuses and functional endoscopic surgery: a critical analysis of 100 symptomatic patients. *Laryngol Otol.* 1991;105:181-85.
15. Weinberger DG, Anand VK, AL-Rawi M, Cheng HI, Messina AV. Surgical anatomy and variations of the onodi cell. *AM J Rhinol.*1996;10:365-70.
16. Liu X, Zhan G, Xu G. Anatomic variations of osteomeatal complex and correlation with chronic sinusitis: CT evaluation. *Zhonghua Er Bi Yan Hou Ke Za Zhi.*1999;34:143-46.
17. Kennedy DW, Zinreich SJ. The functional endoscopic approach to inflammatory sinus disease: current perspectives and technique modifications. *Am J Rhinol* 1988; 2:89-96.
18. Kayalioglu G, Oyar O, Govsa F. Nasal Cavity and paranasal sinus bony variations: a computed tomographic study. *Rhinology.*2000;38:108-13.
19. Alkire BC, Bhattacharyya N. An assessment of sinonasal anatomic variants potentially associated with recurrent acute rhinosinusitis. *Laryngoscope.*2010;12:631-34.
20. Earwaker J: Anatomic variations in sinonasal CT. *Radiographics,*1993;13:381-415.